

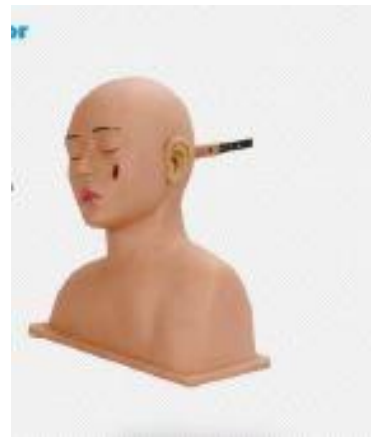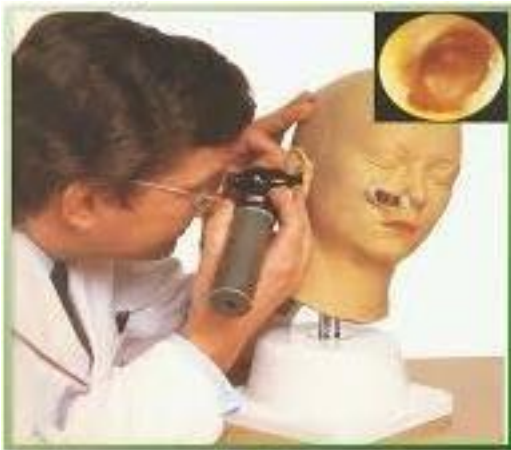دانشگاه علوم پزشکی و خدمات بهداشتی و درمانی کاشان
دانشکده پزشکی - مرکز آموزشی مهارت‌های بالینی
مولاژهای آموزشی معاینات

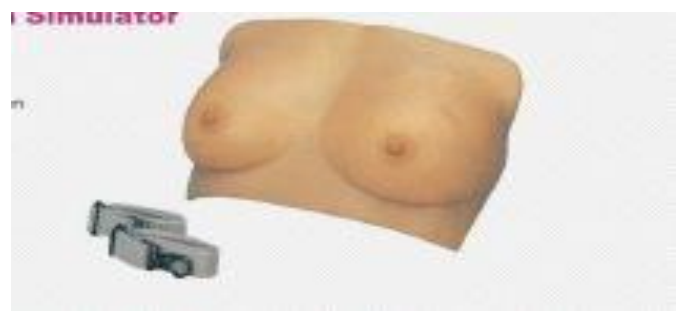
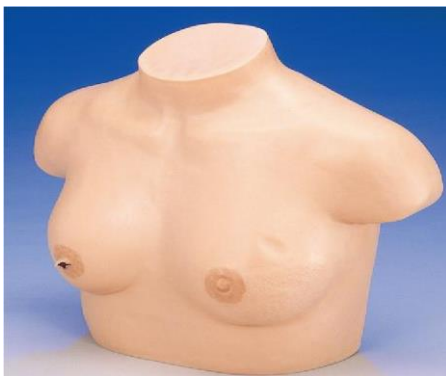
معاینه چشم


معاینه گوش



معاینه برست



معاینه پروستات



Figural describe the rectal cancer, grade, stage, site, characteristics of the prostate.

2. Rectum palpation:

1. Normal rectum
2. Rectum polyps: Most is solitary, with peduncular polyp.
3. Early rectum cancer: Palpable of tumor nodules on rectal wall surface, hard texture.
4. advanced rectum cancer: Little big tumor nodules are palpable on rectal wall surface, with uneven surface, hard texture, the late development stage of rectum cancer.

The image displays anatomical models of the rectum. On the left, three models show the normal, smooth, and uniform structure of the rectum. On the right, a larger model shows a more advanced stage of rectal cancer, characterized by a large, irregular, and nodular mass protruding from the rectal wall.

معاینه رکتال